



A Mediastinal Abscess Developing after Endoscopy to Remove an Ingested Foreign Body: An Unusual Clinical Presentation

Yabancı Cisim Yutulmasına Yönelik Yapılan Endoskopi Sonrası Gelişen Mediastinal Apse: Atipik Klinik Prezantasyon

Emel Ataş Berksoy¹, Feray Arı¹, Özlem Bekem Soylu¹, Şenol Öztürk², Murat Arı⁴, Tanju Çelik¹, Miray Karakoyun³

¹Dr. Behçet Uz Children Hospital, Emergency Service, İzmir, Turkey

²Dr. Behçet Uz Children Hospital, Clinic of Pediatric Surgery, İzmir, Turkey

³Tepecik Training and Research Hospital, Clinic of Pediatric Gastroenterology, İzmir, Turkey

⁴Adnan Menderes University Faculty of Medicine, Department of Biochemistry, Aydın, Turkey

Abstract

Foreign body ingestion is a common household accident in children. Interestingly, 10-20% of such cases require endoscopy. Perforation is the most serious complication of endoscopic procedures, and patients with esophageal perforations can develop mediastinitis and mediastinal abscesses. Early diagnosis reduces mortality, but diagnosis is often delayed because patients who develop mediastinal abscesses present differently. A 9-year-old female patient was admitted to the hospital with abdominal pain. Remarkably, she was in the opisthotonus position. When her history was analyzed in detail, she was found to have recently undergone endoscopy for removal of an ingested coin. She was diagnosed with mediastinal abscess by thoracic magnetic resonance imaging. In this report, we describe the unique case of a patient admitted to the emergency department with abdominal pain who developed mediastinal abscess after endoscopic removal of an ingested coin.

Keywords: Child, endoscopy, mediastinal abscess, esophageal perforation

Öz

Çocukluk çağında, yabancı cisim yutma olayları sık karşılaşılan bir durumdur. Hastaların ancak %10-20'lik kısmı endoskopik müdahaleye ihtiyaç duyar. Perforasyon endoskopik girişimin en ciddi komplikasyonu olup görülme sıklığı %0,03-0,1 arasındadır. Burada özefagusta yabancı cisim nedeniyle yapılan endoskopik işlem sonrası mediastinal abse gelişen olgu sunulmuştur. Karın ağrısı yakınması ile başvuran hastanın fizik bakışında opistotonus pozisyonu, batında istemli defans, torakospinal alanda palpasyonla belirgin hassasiyet saptandı. Diğer sistem bakıları olağandı. Yapılan incelemelerinde akut faz yüksekliliği mevcuttu. Olası spinal kaynaklı patolojileri dışlamak amacıyla yapılan spinal manyetik rezonans görüntülemesinde orta ve alt mediastende, özefagus lokalizasyonunda, kalın duvar yapısı gösteren ve yoğun kontrastlanan, içerisinde hava ve sıvıya bağlı sinyal değişiklikleri bulunan kitle; abse saptandı. Olgunun öyküsü derinleştirildiğinde bir gün öncesinde özefagus birinci darlığında para takılması nedeniyle rijid endoskopi uygulandığı öğrenildi. Sonuç olarak, yabancı cisim yutma, çocukluk çağında sık karşılaşılan bir durum olmakla beraber endoskopik girişimler sonucu nadir de olsa komplikasyonlarla karşılaşılmaktadır. Hastalar, çok farklı klinik tablolarla acil servislere başvurabilirler. Olgu atipik prezantasyonu ve ayırıcı tanıda anamnezin öneminin vurgulanması nedeniyle sunulmuştur.

Anahtar Kelimeler: Çocuk, endoskopi, mediastinal apse, özefagus perforasyonu

Introduction

Esophageal perforation is often caused by trauma, but, nowadays, the most common cause is iatrogenic; perforations develop during endoscopy with diagnostic or curative intent.^{1,2} The most serious complication of endoscopy is perforation,

which occurs in 0.03-0.1% of all patients. Fulminant mediastinitis and mediastinal abscesses have been reported in 1% of patients with esophageal perforations.³ Injuries to the esophagus are routinely classified by location: Cervical, thoracic, and intraperitoneal. If esophageal perforation occurs, the location is not very important; however, location

Address for Correspondence/Yazışma Adresi: Emel Ataş Berksoy MD, Dr. Behçet Uz Children Hospital, Emergency Service, İzmir, Turkey

Phone: +90 505 252 06 55 **E-mail:** emelberksoy@hotmail.com

Received/Geliş Tarihi: 05.05.2016 **Accepted/Kabul Tarihi:** 02.07.2016

©Copyright 2016 by Society of Pediatric Emergency and Intensive Care Medicine
Journal of Pediatric Emergency and Intensive Care Medicine published by Galenos Yayınevi.

is extremely important in mediastinal contamination and infection. A perforation can be fatal if not diagnosed early and properly treated.^{4,5}

Herein, we present a case of a mediastinal abscess caused by iatrogenic injury; a patient suffering from acute abdominal pain presented uniquely. The report shows that an esophageal perforation caused by an iatrogenic injury can be safely treated conservatively.

Case

A 9-year-old female patient was admitted to the emergency department at our hospital because of abdominal pain of 1-day in duration. She was in the opisthotonus position and was sensitive to abdominal palpation. However, all other systems and vital findings were normal. When her history was analyzed in detail, she was found to have undergone upper gastrointestinal tract endoscopy for removal of an ingested coin in another hospital 2 days prior. She had accidentally swallowed a coin, but within 6 hours, the coin had been endoscopically removed without any apparent problem. She was discharged after 2 hours and began to eat, but complained of abdominal pain over the next 10 hours. The laboratory data were as follows: White blood cells, $13.930 \times 10^3/\mu\text{L}$; neutrophils, $10.250 \times 10^3/\mu\text{L}$; hemoglobin, 12.7 g/dL; hematocrit, 39%; and platelets, $336.000 \times 10^3/\mu\text{L}$. The liver and kidney function test results were normal. The amylase level was 49 IU/L, and the C-reactive protein level was 7.48 mg/dL. The erythrocyte sedimentation rate was 68 mm/h, and the full urine analysis was normal. No pathological finding was evident on abdominal or chest x-ray. An abdominal ultrasound scan was normal. A pediatric surgeon was consulted to rule out acute abdominal pathology. Emergency surgical intervention was not indicated. Although the classical symptoms and findings were lacking, mediastinitis was considered because of the possibility of iatrogenic perforation during endoscopy. The patient had no complaint before endoscopy; her complaints began and progressed 1-2 hours after endoscopy. Thoracic and mediastinal magnetic resonance imaging (MRI) supported the diagnosis of a mediastinal abscess of the thoracoabdominal junction toward the left para-aortic region of the subcarinal areas of the middle and lower mediastinum (Figure 1). A mass lesion with a thick wall and intensely contrasting signal changes was evident upon endoscopy. She was deemed to have been iatrogenically injured during esophagoscopy. She was referred to the pediatric surgery unit; oral feeding was discontinued, and intravenous meropenem, vancomycin, fluconazole, and metronidazole (antibiotics) were given. She was not permitted to take any liquid or food orally; she received total parenteral nutrition. The images were assessed in a radiology

council. The abscess was considered to be well confined, not invading the surrounding tissue, and showing no sign of mediastinitis. Surgery was not considered because of possible iatrogenic complications and the fragile thin-walled nature of the esophagus. On the sixth day of admission, her clinical and laboratory results showed that she had responded well to the antibiotics, and she underwent esophageal fluoroscopic imaging. No leakage was apparent, and oral feeding began on the seventh day. This was well tolerated, and the declines in clinical signs and symptoms were followed by regression of the lesion as evidenced by MRI performed on day 18 (Figure 2). Antibiotic treatment was completed by 3 weeks, and she was discharged.

Discussion

In childhood, foreign body ingestion is a common household accident. These cases rarely require endoscopy. In approximately 92.5% of cases encountered, the foreign

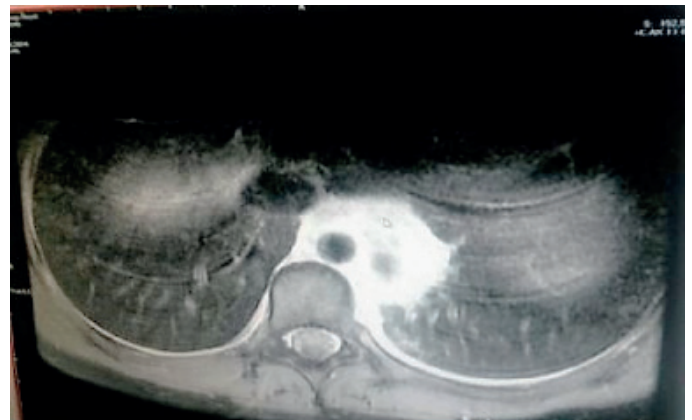


Figure 1. High signal areas associated with edema and inflammation with T2 images of mediastinal magnetic resonance imaging on mediastinum subcarinal area from thoracoabdominal junction towards the left paraaortic field (before the treatment)

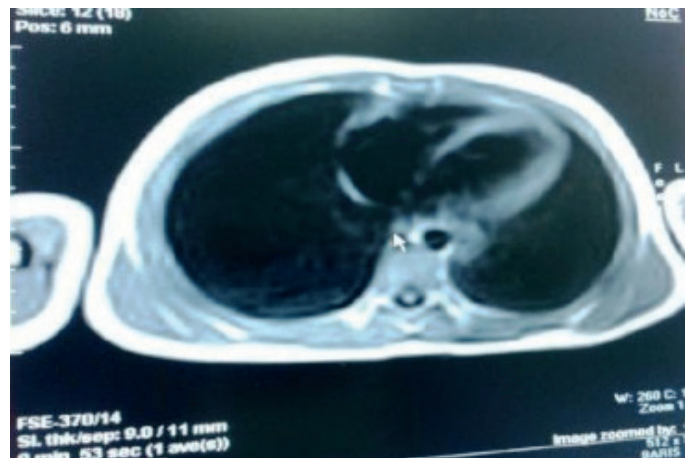


Figure 2. Regression of high signal areas with T2 images of mediastinal magnetic resonance imaging on mediastinum subcarinal area from thoracoabdominal junction towards the left paraaortic field (on 2 weeks of the treatment)

objects are passed in the stool without the need for any medical initiative. The nature of the foreign body ingested and its location after settling in the gastrointestinal tract are of importance when exploring treatment options.⁶⁻¹⁰

Injuries caused by ingestion of a foreign body develop in the physiological stenosis of the pharyngoesophageal area, the cross section of the aortic arch, and the cardio-esophageal region.¹ If the foreign body remains in the esophagus for 2-4 weeks, a pressure lesion may develop. To prevent this, endoscopic procedures are required. During such procedures, mediastinal infections may be triggered by esophageal injuries.⁴ Such cases present to emergency departments with different clinical symptoms. One presentation is abdominal pain combined with the opisthotonus position, as in our case. Early diagnosis effectively reduces mortality. Generally, fever, palpitations, and chest pains are the most common complaints.⁵ However, diagnosis can be delayed because of variations in clinical presentation. Our patient complained of abdominal pain 12 hours after endoscopic removal of the ingested coin. She was admitted in the opisthotonus position, which is a remarkable example of a unique clinical presentation. Patients may present with acute abdominal pain, as did our case, depending on the location of the esophageal perforation. Thus, if any sign or symptom develops after an endoscopic procedure, a diagnosis of mediastinitis or a mediastinal abscess should be kept in mind.

Differences in presenting complaints, analyses of patient histories, and further investigations of the complaints are important in terms of differential diagnosis. Typically, general antibiotics alone are not enough when treating a mediastinal abscess or mediastinitis. Surgical drainage of the abscess is required using a cervical or thoracic procedure.^{3,11} In our case, pediatric surgeons preferred to not operate because the infection was well confined (thus not spreading), there was no sign of mediastinitis, and they sought to avoid possible iatrogenic complications.

Early diagnosis of a mediastinal abscess changes the treatment strategy and reduces mortality. Therefore, in patients with a history of endoscopy, a mediastinal abscess and/or mediastinitis (rare complications of esophageal perforation) should be considered during differential diagnosis. If the diagnosis is made before significant contamination develops, an esophageal perforation can be safely treated conservatively.

Ethics

Informed Consent: Consent form was obtained from the patient.

Peer-review: Externally and Internally peer-reviewed.

Authorship Contributions

Surgical and Medical Practices: Şenol Öztürk, Emel Aktaş Berksoy, Özlem Bekem Soylu, Feray Arı, Concept: Emel Aktaş Berksoy, Design: Emel Aktaş Berksoy, Data Collection or Processing: Feray Arı, Murat Arı, Analysis or Interpretation: Emel Berksoy, Tanju Çelik, Literature Search: Emel Aktaş Berksoy, Miray Karakoyun, Writing: Emel Aktaş Berksoy, Feray Arı.

Conflict of Interest: No conflict of interest was declared by the authors.

Financial Disclosure: The authors declared that this study received no financial support.

References

1. Nirula R. Esophageal perforation. *Surg Clin North Am.* 2014;94:35-41.
2. Eisen GM, Baron TH, Dominitz JA, Faigel DO, Goldstein JL, et al. Guideline for the management of ingested foreign bodies. *Gastrointest Endosc.* 2002;55:802-6.
3. Marty-Ane CH, Alauzen M, Alric P, Serres-Cousine O, Mary H. Descending necrotizing mediastinitis. Advantage of mediastinal drainage with thoracotomy. *J Thorac Cardiovasc Surg.* 1994;107:55-61.
4. Mearin F, Armengol JR, Chicharro L, Papo M, Balboa A, et al. Forceful dilatation under endoscopic control in the treatment of achalasia: a randomised trial of pneumatic versus metallic dilator. *Gut.* 1994;35:1360-2.
5. Chou SL, Chern CH, Chen JD, How CK, Wang LM, et al. Descending necrotising mediastinitis: a report of misdiagnosis as thoracic aortic dissection. *Emerg Med J.* 2005;22:227-8.
6. Arana A, Hauser B, Hachimi-Idrissi S, Vandenplas Y. Management of ingested foreign bodies in childhood and review of the literature. *Eur J Pediatr.* 2001;160:468-72.
7. Suita S, Ohgami H, Nagasaki A, Yakabe S. Management of pediatric patients who have swallowed foreign objects. *Am Surg.* 1989;55:585-90.
8. Passali D, Gregori D, Lorenzoni G, Cocca S, Loglisci M, et al. Foreign body injuries in children: a review. *Acta Otorhinolaryngol Ital.* 2015;35:265-71.
9. Yalcin S, Karnak I, Ciftci AO, Senocak ME, Tanyel FC, et al. Foreign body ingestion in children: an analysis of pediatric surgical practice. *Pediatr Surg Int.* 2007;23:755-61.
10. Aydogdu S, Arikan C, Cakir M, Baran M, Yuksekkaya HA, et al. Foreign body ingestion in Turkish children. *Turk J Pediatr.* 2009;51:127-32.
11. Brook I. The role of anaerobic bacteria in mediastinitis. *Drugs.* 2006;66:315-20.