



Evaluation of Children Who Swallowed Safety Pins

Çengelli İğne Yutan Çocukların Değerlendirmesi

Uğur Deveci, Yaşar Doğan, Abdullah Murat Kayaokay, Şükran Akgeyik, Ferhat Karakoç, Muhammed Ali Çınar

Firat University Faculty of Medicine, Department of Pediatrics, Division of Pediatric Gastroenterology, Hepatology and Nutrition, Elazığ, Turkey

Abstract

Introduction: Cases of swallowed safety pins are often observed in Turkey because of the tradition of pinning a blue eye bead on children to ward against evil. This study aimed to evaluate the diagnosis, endoscopic management, and long-term follow-up of children who were admitted to our hospital with a complaint of swallowing safety pins.

Methods: A retrospective evaluation was made of the clinical characteristics of 47 pediatric patients who were treated because of a swallowed safety pin between 2010 and 2022 in a tertiary level healthcare center.

Results: The cases comprised 24 (51.1%) females and 23 (48.9%) males with a median age of 10 months (range, 5 months-15 years). The median age of the females was observed to be approximately 5 months older than that of males ($p<0.003$). Of the total sample, 40 (85%) infants were breastfed. In all cases, the foreign body had been swallowed by accident. The majority of the cases ($n=25$, 53.2%) were resident in the province where the hospital is located, and the other cases presented from surrounding provinces. The localization of the swallowed safety pin in the gastrointestinal system was observed in the stomach ($n=26$, 65.3%), first esophageal stricture ($n=10$, 21.3%), second esophageal stricture ($n=6$, 12.8%), third esophageal stricture ($n=2$, 4.2%), duodenum ($n=3$, 6.4%), and cecum ($n=3$, 6.4%). The safety pin was removed endoscopically in 31 (66%) cases. In 2 cases, the safety pin was observed to be lodged in the duodenum. Of the pins removed, the end was open in 25. In 15 cases, as the safety pin was seen to be closed, it was left for spontaneous elimination. Surgery was required in 1 case because the safety pin was embedded in the cecum. No complications were observed in any patient during or after the procedures.

Conclusion: The swallowing of safety pins is frequently observed, especially in the breastfeeding period of infants. In most cases, safety pins can be safely removed using an endoscopic method without complications.

Keywords: Foreign body ingestion, safety pin, child, endoscopy

Öz

Giriş: Ülkemizde çocuklara nazar boncuğu takma geleneği nedeniyle çengelli iğne yutma olgularına sık rastlanmaktadır. Bu çalışmada hastanemize çengelli iğne yutma şikayetiyle başvuran çocukların tanı, endoskopik yöntemle tedavisi ve uzun dönem izlemlerinin değerlendirilmesi amaçlandı.

Yöntemler: Bir üçüncü basamak sağlık merkezinde 2010-2022 yılları arasında çengelli iğne yutma nedeni ile değerlendirilmiş olan 47 çocuk olgunun klinik özellikleri geriye dönük olarak değerlendirildi.

Bulgular: Olguların 24'ü (%51,1) kız ve ortanca yaşları 10 ay (5 ay-15 yıl) idi. Kız çocukların ortanca yaşının erkek çocuklardan yaklaşık 5 ay daha büyük olduğu gözlemlendi ($p<0,003$). Bu çocuklardan 40'ı (%85) süt çocuğu idi. Olguların tümü yabancı cismi kazayla yutmuştu. Olguların çoğunluğu ($n=25$, %53,2) hastanemizin bulunduğu ilde, diğerleri ise çevre illerden başvurmuştu. Çengelli iğnelerin gastrointestinal sistemde buldukları yerlerin sırası ile mide ($n=26$, %65,3), özofagus 1. darlık ($n=10$, %21,3), özofagus 2. darlık ($n=6$, %12,8), özofagus 3. darlık ($n=2$, %4,2), duodenum ($n=3$, %6,4) ve çekum ($n=3$, %6,4) olduğu görüldü. Çengelli iğne endoskopik olarak olguların 31'inde (%66) çıkarılabildi. Bu olgulardan 2'sinde çengelli iğnenin duodenuma saplanmış olduğu gözlemlendi. Çıkarılan çengelli iğnelerin 25'inin ucu açık idi. Olguların 15'inde ucu kapalı çengelli iğnenin izlem sonucunda kendiliğinden çıktığı gözlemlendi. Bir olguda çengelli iğne çekuma gömüldüğü için cerrahi yolla çıkarıldı. İşlemler sırasında ve sonrasında hiçbir olguda herhangi bir komplikasyon gözlenmedi.

Sonuç: Çengelli iğne yutma özellikle süt çocukluğu döneminde sık görülmektedir. Olguların çoğunda çengelli iğneler endoskopik yöntemle güvenli ve komplikasyonsuz bir şekilde çıkarılabilmektedir.

Anahtar Kelimeler: Yabancı cisim yutma, çengelli iğne, çocuk, endoskopi

Address for Correspondence/Yazışma Adresi: Uğur Deveci, Firat University Faculty of Medicine, Department of Pediatrics, Division of Pediatric Gastroenterology, Hepatology and Nutrition, Elazığ, Turkey

E-mail: ugurdeveci23@hotmail.com **ORCID ID:** orcid.org/0000-0002-5395-8250

Received/Geliş Tarihi: 12.10.2023 **Accepted/Kabul Tarihi:** 25.12.2023

*This study was presented as an oral presentation at the 3rd Eastern Pediatrics Congress held in Diyarbakır between 28 September 1 October 2023.



Introduction

Foreign body ingestion continues to be a significant health problem that is frequently seen throughout the world,¹ and is seen more often especially in children below the age of 5 years.² It is reported to lead to the death of approximately 1500 children per year in the United States.³ Although 80% of foreign bodies in the gastrointestinal system are eliminated spontaneously, they can sometimes lead to severe morbidity and even death.⁴ It has been reported that safety pins swallowed by children constitute 1% of foreign body aspirations, but this rate is higher in some regions of the world.⁵ Studies in Turkey have reported that safety pin swallowing constitutes 8-14% of foreign body aspiration in children.^{6,7} There is a cultural tradition in Turkey of attaching blue beads and gold to infants with a safety pin. Infants often pull the safety pin out and open it; thus, an open-ended safety pin is accidentally swallowed.⁸ Cervical, thoracic, and abdominal radiographs are used to determine the location of the foreign body.² Safety pins can be removed easily and without complications using the endoscopic method.¹ Safety pins that cannot be removed or seen with the endoscopic method must be followed with radiography until they spontaneously pass. Those that do not spontaneously pass out may need to be surgically removed.⁶ This study aimed to evaluate the diagnosis, endoscopic management, and long-term follow-up of children who were admitted to our hospital with a complaint of swallowing safety pins.

Materials and Methods

Approval for this study was granted by the Non-Interventional Research Ethics Committee of Firat University (decision no: 16/25, dated: 29.12.2022). This retrospective study included 47 pediatric patients who presented at the Pediatric Gastroenterology, Hepatology, and Nutrition Clinic of Firat University Medical Faculty Hospital between 2010 and 2022 with the complaint of a swallowed safety pin. The patient records were examined in detail, and the clinical, endoscopic, and radiological data were recorded on a form created for the study.

Statistical Analysis

Data obtained in the study were statistically analyzed using IBM SPSS version 22 software. The Mann-Whitney U test was used in the statistical evaluations. Results are expressed as mean \pm standard deviation (SD). A value of $p < 0.05$ was accepted as statistically significant.

We used an algorithmic proposal for the technique of endoscopic removal of ingested safety pins (Figure 1).

Informed consent was obtained from the parents of all the children before the endoscopy procedure.

Endoscopic Procedure

To determine the localization of the foreign body, neck, chest, and abdominal radiographs were obtained from all patients. In cases where a safety pin was detected in the esophagus, upper gastrointestinal endoscopy was urgently performed, regardless of fasting status, because of the risk of perforation. In cases where the safety pin was determined in the esophagus, an emergency upper endoscopy procedure was performed because of the risk of perforation. The safety pin in the esophagus was pushed into the stomach. In cases with an empty stomach during the endoscopy, the safety pin was removed immediately. In cases where the stomach was determined to be full of food, endoscopy was repeated after 6-8 h and the safety pin was removed. In cases of safety pins detected in the stomach and duodenum, a 6-h fasting period was waited. Midazolam was administered at a dose of 0.1 mg/kg for sedation in all cases. Following this procedure, sedation was terminated with the administration of flumazenil. The patients were monitored after the procedure, and oral feeding was started 2-4 h later. Then, children without nausea or vomiting during follow-up were discharged.

Flexible gastroscopes, 5 mm and 9 mm in diameter (Olympus 170, 190, and 260, Tokyo, Japan) were used during the esophagogastroduodenoscopy procedures. To remove foreign bodies, rat-tooth and crocodile-mouth forceps were used. Immediately after removal of the foreign body, endoscopy was repeated to evaluate the gastrointestinal mucosa. Cases in which the foreign body could not be visualized or removed during endoscopy were followed up with radiographs until spontaneous elimination of the foreign body.

In addition to the clinical and laboratory findings of the children who swallowed safety pins, endoscopic and radiological data were examined. Treatment and complications were investigated, and the data were compared with the relevant literature.

Results

The 47 cases comprised 24 (51.1%) females and 23 (48.9%) males with a mean age of 10 months (range, 5 months-15 years). The mean age of the children was 12 months for females and 7 months for males, and the difference between the genders was determined to be statistically significant ($p < 0.003$). The distribution of cases by age and gender is shown in Table 1. In all cases, the foreign body had been swallowed by accident. It was determined that the most common complaint was the family noticing that the child had

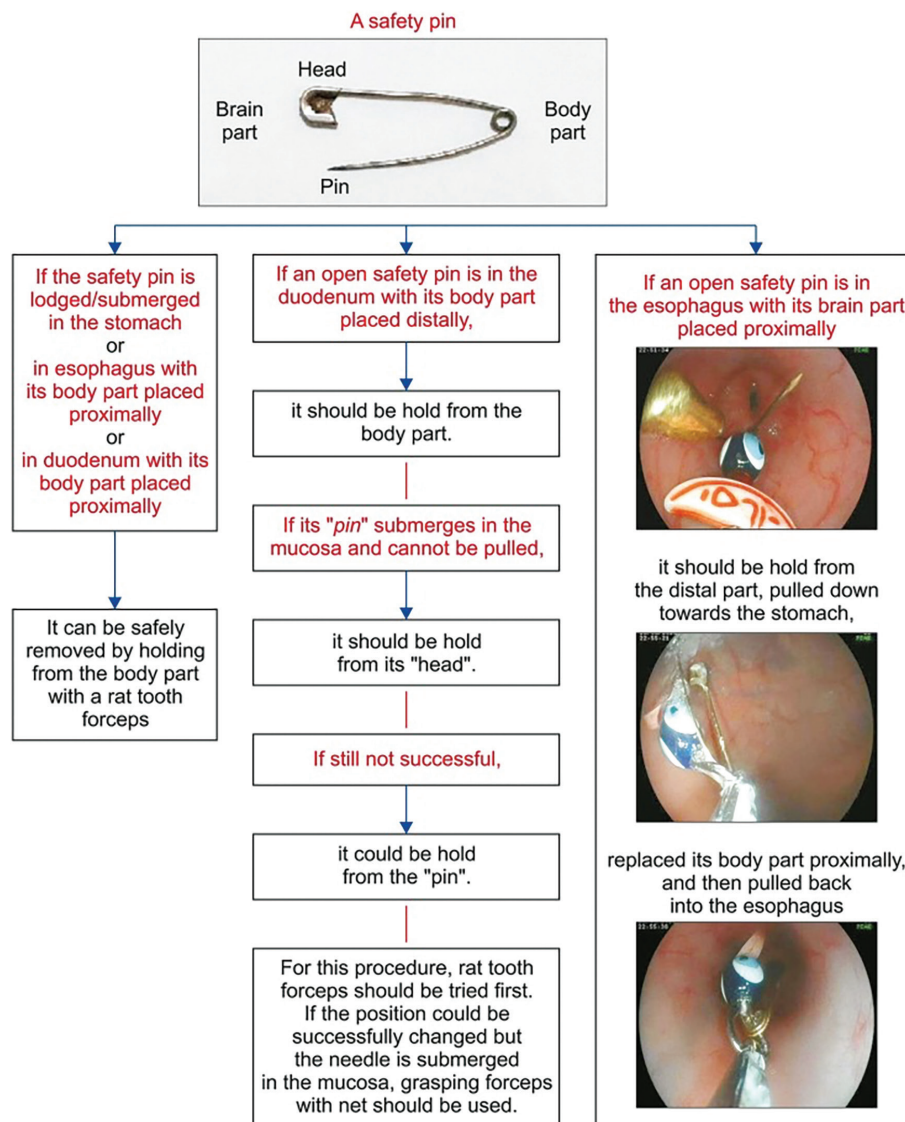


Figure 1. Algorithmic proposal for the technique of endoscopic removal of ingested safety pins

swallowed a foreign object, inability to suckle in infants, and difficulty swallowing in older children.

Most presentations were seen to have been made in March and the fewest in January. The province of residence of the cases was primarily Elazığ, followed by Bingöl, Muş, and Van. The place of residence of the patients and their distance in kilometers and hours by road to the endoscopy center are given in Table 2.

The time from swallowing the safety pin to presentation at the hospital was examined, and this time was 3-6 h for patients who lived in the province where the hospital is located. Cases coming from outlying towns in the same province presented within 6-12 h, and cases accepted from other provinces were seen to have presented at the pediatric emergency department within 12-48 h.

Radiological and endoscopic examinations revealed that the safety pin was localized most often in the stomach, followed by the first esophageal stricture and the second esophageal stricture (Table 3, Figure 2). An open-ended safety pin in the stomach is shown in Figure 3. The safety pin was observed to have lodged in the duodenum in two cases, and these were removed endoscopically (Figure 4).

The safety pins were removed by the endoscopic route in 31 (66%) cases and with surgery in 1 case because the safety pin was embedded in the cecum. Of the safety pins removed endoscopically, 25 were observed to be open. The 15 cases in which the foreign body could not be removed or seen by the endoscopic method was followed up with daily radiological imaging in the hospital and waited to pass spontaneously.

Table 1. Distribution of subjects by age and gender

Gender	Number	Percentage	Minimum age	Maximum age	Mean age
Male	23	48.9	6 months	3 years	7 months
Female	24	51.1	5 months	15 years	12 months
Total	47	100	5 months	15 years	10 months

Comparisons of the ages of male and female children $p < 0.003$

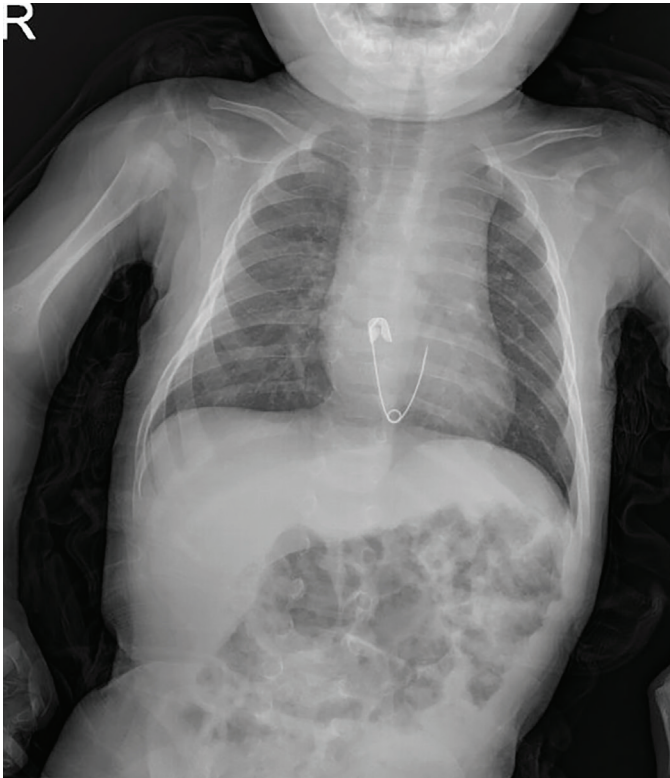

Figure 2. Radiological appearance of an open-ended safety pin in the medial esophagus

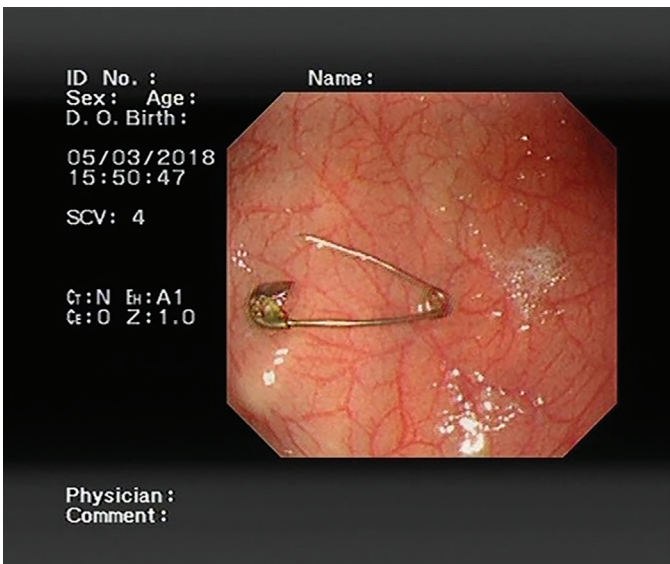


Figure 3. Endoscopic appearance of an open-ended safety pin in the stomach fundus

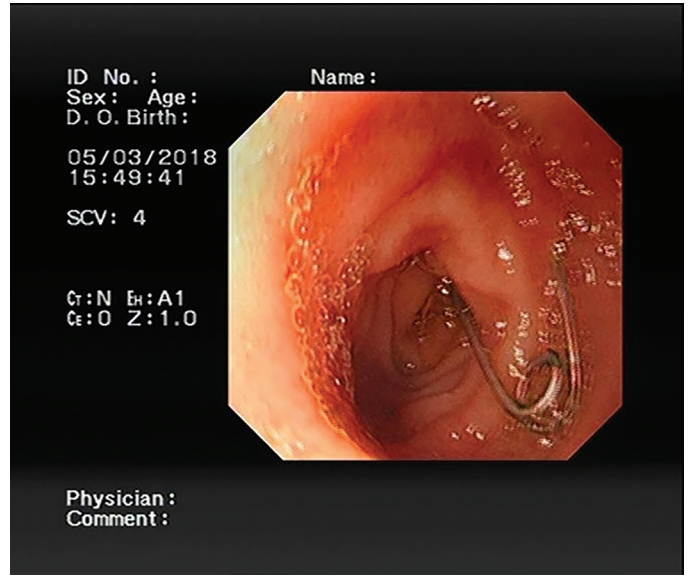


Figure 4. Endoscopic appearance of an open-ended safety pin lodged in the duodenum

Table 2. Places of residence of the cases and their distance to the center where endoscopy was performed

Place of residence	Number and percentage of cases (n, %)	Distance by road in kilometers	Distance by road in hours
Elazığ	25 (53.2)	-	-
Adıyaman	1 (2.1)	240	4
Bingöl	6 (12.8)	140	2
Bitlis	1 (2.1)	390	6
Diyarbakır	1 (2.1)	150	2
Kars	1 (2.1)	520	7
Malatya	1 (2.1)	100	1.5
Muş	5 (10.6)	260	3.5
Siirt	1 (2.1)	340	5
Tunceli	1 (2.1)	80	1.5
Van	3 (6.4)	520	7

Other than erosion due to the procedures used to remove the foreign body, no complications such as perforation or death were observed in any case.

Discussion

Safety pin aspirations are frequently seen in young children and can cause serious morbidity and mortality. The aim of

Table 3. Radiological and endoscopic localization of the safety pin

Localization	Number (n)	Percentage (%)
First esophageal stricture	10	21.3
Second esophageal stricture	6	12.8
Third esophageal stricture	2	4.3
Stomach	26	55.3
Duodenum	2	4.3
Cecum	1	2.1
Total	47	100

this study was to draw attention to the fact that safety pins can be safely and rapidly removed using the endoscopic method. In a previous study, 14 (70%) of 20 children who had swallowed safety pins were determined to be female, and the mean age of the cases was reported to be 9.5 months (range, 3.5-140 months).⁸ In another study that examined 15 cases of ingested safety pins, the mean age was reported to be 5.4 years (range, 7 months-16 years).⁹ The age of 7 infants who had swallowed safety pins in another study was in the range of 3.5-12 months, and 4 (57%) cases were female.¹⁰ In a study of 49 children who swallowed safety pins, the mean age was reported to be 8 months (range, 4-24 months), and 30 cases (61%) were male.¹¹ A study published in 2016 reported a mean age of 11 months (range, 4 months-4 years) of children with ingested safety pins.⁷ Although differences can be seen in the ages of children who have swallowed safety pins, this is generally seen in children younger than 5 years.¹² The present study findings are consistent with the data in the literature.

In the current study, 25 (53.2%) of the cases were residents of Elazığ, and 22 (46.8%) came from surrounding provinces. The cases who lived in the center of the province reached the hospital in a short time (3-6 hours), and as the distance increased, the time to presentation increased (3-48 hours).

Although the rate of safety pins within foreign bodies swallowed by children is low, they can lead to life-threatening complications. A study from another country reported this rate to be 3.3%.¹³ In Turkey, it has been reported that safety pins are swallowed by 36-47% of children who have ingested a foreign body.^{14,15} More recent studies published in 2015 and 2016 in Turkey reported that safety pins were swallowed by 8-14% of cases of foreign body ingestion.^{6,7} The decrease in this rate in Turkey over the years can be considered to be due to an increase in the socio-economic and cultural levels.

Localization of the swallowed safety pins was observed most often in the stomach, followed by the first and second esophageal strictures. Previous studies have determined that safety pins are most often localized in the esophagus, stomach, and duodenum.^{6,8} Our study findings are consistent with data in the literature.

Safety pins can sometimes lodge in the duodenum. In a previous study, 11.5% of ingested safety pins were reported to have stuck in the duodenum, and duodenotomy was performed in these cases.⁷ During endoscopy in the current series, the safety pins were lodged in the duodenum in two cases, and these were removed endoscopically. The low number in the current study was thought to be due to early intervention in the cases.

In one of the current study cases, the safety pin could not be removed endoscopically, and during clinical follow-up, it was observed that the safety pin was embedded in the cecum. Because the safety pin did not emerge spontaneously within 15 days, laparotomy was performed and the pin was removed. It is rare that safety pins become stuck in the colon. In a study by Gün et al.¹¹, as a safety pin remained in the colon for a long-time in one case, laparotomy was performed. Erginel et al.⁷ also reported that laparotomy was performed in only one case because a safety pin remained in the colon for a long period. The present study findings are consistent with the data in the literature.

In this study, no complications were observed because of the rapid and appropriate management approach applied to pediatric patients who swallowed safety pins. The treatment approach we applied was in accordance with the literature.^{1,2,10}

In this study, the number of cases requiring surgical treatment was low compared with the literature. It is thought that this may be because of the rapid and appropriate approach to the cases.

It has been observed that the anxiety and stress on patients and families has decreased because of the rapid and uncomplicated treatment of children who swallowed safety pins using the endoscopic method.

Study Limitations

The limitations of our study are that it is retrospective and the number of cases is low. Because our study population was small, our results cannot be generalized; therefore, multicenter studies covering a larger number of cases are required.

Conclusion

The swallowing of safety pins in pediatric cases is seen most often during the breastfeeding period. Safety pins can be safely removed using an endoscopic method without complications. In recent years, there has been an increase in the number of centers in Turkey where endoscopic procedures can be performed. Children who have swallowed a safety pin must be sent quickly to a center where interventional procedures can be performed, thereby preventing potential morbidity and mortality.

Information: The statistical analysis of the study was conducted by Assoc. Prof. Mehmet Onur Kaya, a faculty

member at Firat University Faculty of Medicine, Department of Medical Statistics.

Ethics

Ethics Committee Approval: Approval for this study was granted by the Non-Interventional Research Ethics Committee of Firat University (decision no: 16/25, dated: 29.12.2022).

Informed Consent: Informed consent was obtained from the parents of all the children before the endoscopy procedure.

Authorship Contributions

Surgical and Medical Practices: U.D., Y.D., Concept: U.D., Y.D., Design: U.D., Y.D., A.M.K., Ş.A., F.K., Data Collection or Processing: U.D., Y.D., A.M.K., Ş.A., F.K., M.A.Ç., Analysis or Interpretation: U.D., Y.D., A.M.K., Ş.A., F.K., Literature Search: U.D., Y.D., M.A.Ç., Writing: U.D., Y.D.

Conflict of Interest: No conflict of interest was declared by the authors.

Financial Disclosure: The authors declared that this study received no financial support.

References

1. Kramer RE, Lerner DG, Lin T, Manfredi M, Shah M, et al. Management of ingested foreign bodies in children: a clinical report of the NASPGHAN Endoscopy Committee. *J Pediatr Gastroenterol Nutr.* 2015;60:562-74.
2. Mowry JB, Spyker DA, Brooks DE, Zimmerman A, Schauben JL. 2015 Annual Report of the American Association of Poison Control Centers' National Poison Data System (NPDS): 33rd Annual Report. *Clin Toxicol (Phila).* 2016;54:924-1109.
3. Uyemura MC. Foreign body ingestion in children. *Am Fam Physician.* 2005;72:287-91.
4. ASGE Standards of Practice Committee, Ikenberry SO, Jue TL, Anderson MA, Appalaneni V, et al. Management of ingested foreign bodies and food impactions. *Gastrointest Endosc.* 2011;73:1085-91.
5. Sink JR, Kitsko DJ, Mehta DK, Georg MW, Simons JP. Diagnosis of pediatric foreign body ingestion: clinical presentation, physical examination, and radiologic findings. *Ann Otol Rhinol Laryngol.* 2016;125:342-50.
6. Dereci S, Koca T, Serdaroğlu F, Akçam M. Foreign body ingestion in children. *Turk Arch Pediatr* 2015;50:234-40.
7. Erginel B, Karlı G, Gün Soysal F, Keskin E, Özbey H, et al. Foreign body ingestion in pediatric patients. *J Faculty Med.* 2016;79:27-31.
8. Demiroren K. A Case series of ingested open safety pin removal using a proposed endoscopic removal technique algorithm. *Pediatr Gastroenterol Hepatol Nutr.* 2019;22:441-6.
9. Sarihan H, Kaklıkkaya I, Ozcan F. Pediatric safety pin ingestion. *J Cardiovasc Surg (Torino).* 1998;39:515-8.
10. Kalayci A, Tander B, Kocak S, Rizalar R, Bernay F. Removal of open safety pins in infants by flexible endoscopy is effective and safe. *J Laparoendosc Adv Surg Tech A.* 2007;17:242-5.
11. Gün F, Salman T, Abbasoglu L, Celik R, Celik A. Safety-pin ingestion in children: a cultural fact. *Pediatr Surg Int.* 2003;19:482-4.
12. Kurowski JA, Kay M. Caustic ingestions and foreign bodies ingestions in pediatric patients. *Pediatr Clin North Am.* 2017;64:507-24.
13. Balekuduru AB, Shetty B, Duttal A, Subbaraj SB. Profile of foreign body ingestion and outcomes of endoscopic management in pediatric population. *J Dig Endosc.* 2017;8:17-23.
14. Aydoğdu S, Arikan C, Cakir M, Baran M, Yüksekaya HA, et al. Foreign body ingestion in Turkish children. *Turk J Pediatr.* 2009;51:127-32.
15. Yalçın S, Karnak I, Ciftci AO, Senocak ME, Tanyel FC, et al. Foreign body ingestion in children: an analysis of pediatric surgical practice. *Pediatr Surg Int.* 2007;23:755-61.